

Radiology Board Exam

Well done! You have successfully stayed awake through Mr. Gonyo's "Medical School" classes and have earned your **Radiology Internship**. Your next step is a two "year" **Residency** program in which you will perform all of the duties of a radiologist including the best part ... billing your patients! You must first, however, demonstrate your competency by passing this little ole **Radiology Proficiency Board Exam (RPB)**. Good luck!

Part 1: The Exam - complete this before doing the X-Rayted Lab. Use your Radiology Reference Guide.

1. What is the name of this exam? _____ Exam
2. A doctor who specializes in reading x-rays and other imaging media is called a _____.
3. Your skeleton is made of living bone cells, _____, _____, _____, and water.
4. Places where bones meet are called _____.
5. Match these joints:

- | | |
|----------------------------------|--------------------|
| _____ neck | a) Ball and socket |
| _____ sacrum, pelvis, cranium | b) Pivot |
| _____ knee, elbows, fingers, jaw | c) Fixed |
| _____ forearm, lower leg | d) Hinge |
| _____ vertebra, hands, feet | e) Swivel |
| _____ shoulders, hips | f) Gliding |

6. A broken bone is called a _____.
7. Match these fractures:

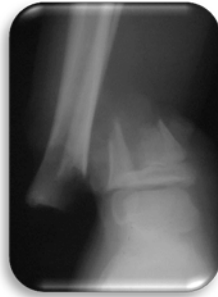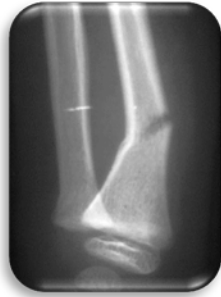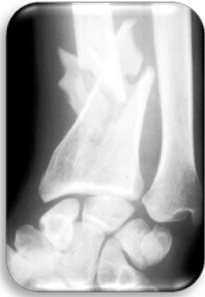- | | |
|-------------------|---|
| _____ Greenstick | a) bone is broken in 3 or more fragments. |
| _____ Hairline | b) bone is flattened out of shape. |
| _____ Stress | c) bone is cracked along a long, thin line. |
| _____ Simple | d) bone is bent and broken on one side only. |
| _____ Comminuted | e) bone is partially broken by repeated stress. |
| _____ Compound | f) bone is broken and punctures skin. |
| _____ Compression | g) bone is broken and does not puncture skin. |

8. Soft tissues show up better when a special dye called a _____ is given to the patient.
9. Look through the "X-ray Files" of your Reference Guide (pp 4-16). List the page number where you would find each of these:

- | | | |
|-----------------------------|----------------------|--------------------------|
| _____ forearm and lower leg | _____ pelvic girdle | _____ lumbar spine |
| _____ thoracic spine | _____ cervical spine | _____ knee |
| _____ rib cage and sternum | _____ wrist | _____ shoulder and elbow |
| _____ the foot | _____ ankle | _____ the hand |

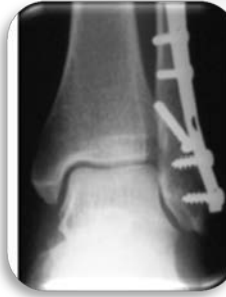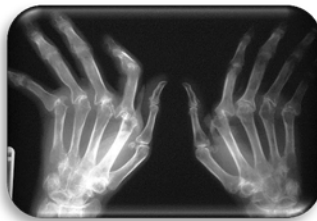

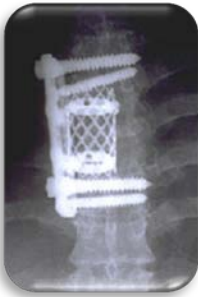
10. Study the "X-ray Files" (page 19) and diagnose these x-rays:




_____ Fracture _____ Fracture _____ Fracture

11. Study the remaining "X-ray Files" and identify these:



12. Before being exposed to X-rays, the film is _____ (Clear / Black / White) pick one

Part2: Patient Survey - complete this after completing the X-Rayted Lab. (see next page)



Patient Personal Information Survey

Match the following about your patients: (answers can be used more than once)

_____ Horse was attacked by a killer skunk.

_____ Elephant sat on her leg.

_____ Inhaled judge's pen.

_____ Tumbled off uneven parallel bars.

_____ Won consolation prize ... a new pair of glasses.

_____ Stuck arm into elevator door.

_____ Caught by the big toe with a fishing hook.

_____ Fell from tree and stuck out arm to break fall.

_____ Broke his collar bone.

_____ Suffered a spiral fracture.

_____ World's most astonishing mishap.

_____ Suffered a badly broken femur.

_____ Broke his humerus but is not laughing.

a) Leonard Karpofolitz

b) Arnold Schwartzensniffler

c) Miles Giles


d) Yoloff Svenson

e) Polly Perkowitz

f) Lenny Crawford

g) Yolanda Flugelhoffer

h) Yoloff's grandson



"Well, first the bad news —
you're definitely hooked."